



## Protective Effect of *Ricinus communis* Leaves Extract on Carbon Tetrachloride Induced Hepatotoxicity in Albino Rats

Evan Sabina Prince<sup>a</sup>, Poorna Parameswari<sup>b</sup>, Rasool Mahaboob Khan<sup>c,\*</sup>

<sup>a</sup>School of Biotechnology, Chemical and Biomedical Engineering, VIT University, Vellore - 632 014, India.

<sup>b</sup>Postgraduate Department of Biochemistry, Bharathi Women's College, Chennai-108, India

<sup>c</sup>Faculty of Health and Life Sciences, Management and Science University Shah Alam, Malaysia.

---

### Abstract

*Ricinus communis* Linn. (Euphorbiaceae) is a soft wooded tree widely prevalent throughout tropics regions of the world which have a warm temperature. In the Indian system of medicine, the leaves, roots and seed oil of this plant have been used for the treatment of inflammation and liver disorders for a long time. In the present study, the protective effects of ethanol extract of *Ricinus communis* L. leaves on carbon tetrachloride-induced liver damage were investigated in rats. Results were compared with those of silymarin, a standard hepatoprotective drug. It was found that an increase in the activities of serum transaminases and the level of liver lipid peroxidation, protein, glycogen and the activities of acid and alkaline phosphatase in liver induced by CCl<sub>4</sub> were significantly inhibited by treatment with *Ricinus communis* ethanolic extract (250/500mg/kg b.wt). In addition, the depletion of glutathione level and adenosine triphosphatase activity observed in the CCl<sub>4</sub>-induced rat liver were effectively prevented by treatment with *Ricinus communis* ethanolic extract (250/500mg/kg b.wt). Histopathological examination further confirmed the hepatoprotective activity of *Ricinus communis* ethanol extract when compared with the CCl<sub>4</sub>-induced control rats. In conclusion, these results indicate that the ethanol extract of *Ricinus communis* ethanolic extract exhibits hepatoprotective action.

**Keywords:** Carbon tetrachloride; Hepatoprotective effect; Lipid peroxidation; *Ricinus communis*; Serum transaminases.

**Received:** August 11, 2010; **Accepted:** February 21, 2011.

---

### 1. Introduction

Hepatitis associated with liver cirrhosis has become one of the most prevalent diseases

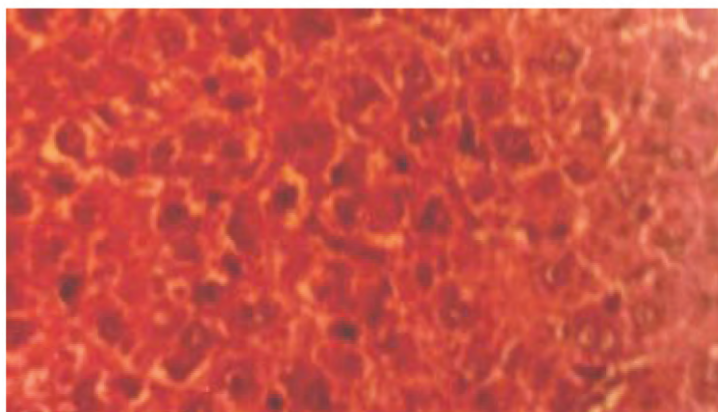
in the world, which can be induced by virus, alcohol or other toxic chemicals [1]. Carbon tetrachloride, an established hepatotoxin, induces toxicity in rats which closely resembles human cirrhosis [2]. Experimentally, liver diseases have been shown to be produced by the administration of carbon tetrachloride (CCl<sub>4</sub>), thioacetamide, paracetamol, etc. CCl<sub>4</sub>-

---

\*Corresponding author: Dr. M. Rasool M. Sc., Ph.D., Faculty of Health and Life Sciences, Management and Science University, 40100 Shah Alam, Selangor Darul-Ehsan, Malaysia.  
E-mail: mkr474@gmail.com

induced hepatotoxicity model is frequently used for the investigation of hepatoprotective effect of drugs and plant extracts on experimental animals. CCl<sub>4</sub> hepatotoxicity depends on the reductive dehalogenation of CCl<sub>4</sub> catalyzed by CYP450 in the liver cell endoplasmic reticulum leading to the generation of an unstable complex of •CCl<sub>3</sub> radical. This trichloromethyl radical reacts rapidly with O<sub>2</sub> to yield trichloromethyl peroxy radical which is reported as a highly reactive species. This free radical attacks microsomal lipids leading to their peroxidation and also covalently binds to microsomal lipids and proteins ultimately initiating a site of secondary biochemical processes which is the ultimate cause of pathological consequences of CCl<sub>4</sub> metabolism [3]. Despite extensive research in the medicine, no drug in the modern system of medicine can be claimed to be effective to cure liver disorders, which in many times become fatal, however, the search for new medicines is still going on [4, 5]. Therefore, many remedies of folk tradition from plant origins are evaluated for its possible antioxidant and hepatoprotective effects against different chemical-induced liver damage in experimental animals.

*Ricinus communis* Linn. (Euphorbiaceae) is a soft wooded tree widely prevalent throughout tropics regions of the world which have a warm temperature [6]. In the Indian system of medicine, the leaves, roots and seed oil of this plant have been used for the treatment of inflammation and liver disorders for a long time [7]. They have been found to be hepatoprotective against galactosamine-induced hepatic damage [8], hypoglycemic [9], laxative [10], diuretic [11] and antibacterial effects [12]. The leaves of *R. communis* found to contain flavanoids like kaempferol-3-0-beta-D-rutinoside and kaempferol-3-0-beta-D-xylopyranoid and tannins [13, 14]. However, scientific studies on its utility in damaged liver are few and the aim of the present study was to confirm the hepatoprotective effect of *Ricinus communis* extract against CCl<sub>4</sub>-induced hepatic injury in rats. In addition, its hepatoprotective effect was compared to the effect of silymarin which is known to be effective against CCl<sub>4</sub>-or acetaminophen-induced liver damages [15].



**Figure 1.** Photomicrographies of paraffin-embedded rat liver. A: Normal Architecture of the liver cell was seen in olive oil alone treated (normal) rats; B: Few hepatocytes showing increased cytoplasmic staining and infiltration of mono nuclear cells around the portal triad and in the lobule were observed in liver of CCl<sub>4</sub> -induced rats; C: Liver showing minimal inflammatory cellular filtration was observed in *Ricinus communis* ethanol extract (250 mg/kg b.wt) treated CCl<sub>4</sub>-induced rats; D: Liver showing marked improvement to normal architecture was observed in *Ricinus communis* ethanol extract (500 mg/kg b.wt) treated CCl<sub>4</sub>-induced rats; E: Liver returned to almost normal architecture was observed in silymarin (50 mg/kg b.wt) treated CCl<sub>4</sub>-induced rats. F: Normal Architecture of the liver cell was seen in *Ricinus communis* ethanol extract (500mg/kg b.wt) alone treated rats. **Figure 1A.**

**Table 1.** Activities of aspartate transaminase (AST) and alanine transaminase (ALT) in serum of normal and experimental rats.

Parameters (IU/L)	Group -I (Control)	Group -II (CCl4-induced)	Group -III (CCl4-induced +Ricinus communis extract 250mg/kg/b.wt)	Group -IV (CCl4-induced +Ricinus communis extract 500mg/kg/b.wt)	Group-V (CCl4-induced + silymarin 50mg/kg/b.wt)	Group -VI (Ricinus communis extract 500 mg/kg/b.wt)
Serum AST	44.4±5.77	237.0±4.64 a*	60.0±5.21 b*	55.0±5.21 b*	54.9±5.2 b*	46.3±3.94
Serum ALT	55.0±7.94	120.4±21.85 a*	65.2±6.91 b*	60.5±6.91 b*	59.5±7.64 b*	57.2±6.75

The values are expressed as mean ± S.D. Each group consists of six animals; Comparisons were made as follows: a: Group II (CCl4-induced) vs. Group I (control); b: Group II vs. Group III (CCl4-induced +Ricinus communis extract 250mg/kg/b.wt); Group IV (CCl4-induced +Ricinus communis extract 500mg/kg/b.wt); Group-V (CCl4-induced + silymarin 50mg/kg/b.wt); The symbol represents the statistical significance at: \* $p < 0.05$ .

## 2. Material and Methods

### 2.1. Animals

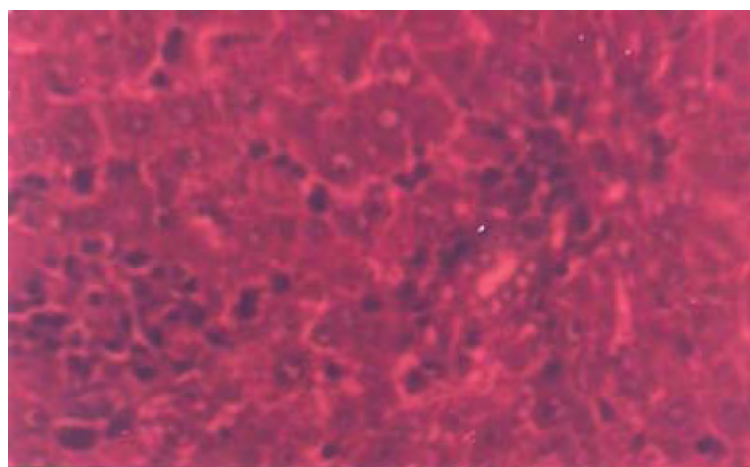
Male albino rats of Wistar strain (140±10 g b.w.) were obtained from the Tamil Nadu Veterinary College, Chennai, India. They were acclimatized for a week in a light and temperature-controlled room with a 12 hr dark-light cycle and fed with commercial pelleted feed (Water 8.9%, Protein 25.4%, Lipid 4.4%, Carbohydrate 50.3%, Ash 6.9%, and Crude fiber 4.1%) from Hindustan Lever Ltd. (Mumbai, India) and water was made freely available. The animals used in this study were treated and cared for in accordance with the guidelines recommended by the Committee for the Purpose of Control and Supervision of Experiments on Animals (CPCSEA), Government of India, Ministry of Culture, Chennai, India. Experimental protocol was approved by the departmental ethical committee.

### 2.2. Preparation of the extract

Fresh leaves of *R. communis* were collected from rural areas around Chennai, India, and it was authenticated by Chief Botanist, VIT University, Vellore, India. The leaves were dried at the room temperature. The dried and powdered leaves of *R. communis* (1 kg) were extracted with 80% ethanol at room temperature for 24 hr. It was then filtered and the filtrate was evaporated and dried in a vacuum desiccator. The percentage yield of the dried extract was 15% from the initial raw material. This dried extract and a reference drug, silymarin, Micro Labs, Tamil Nadu, India were dissolved in water and administered to the animals by oral intubation method, respectively.

### 2.3. Experimental Design

In this study, all group of rats except group I and group VI (negative control) received CCl4 once only. The animals were divided

**Figure 1B.**

**Table 2.** Effect of *R. communis* extract on CCl4-induced liver damage in rats.

Parameters (IU/L)	Group -I (Control)	Group -II (CCl4-induced)	Group -III (CCl4-induced +R. communis extract 250mg/kg/b.wt)	Group -IV (CCl4-induced +R. communis extract 500mg/kg/b.wt)	Group-V (CCl4-induced + silymarin 50mg/kg/b.wt)	Group -VI (R. communis extract 500 mg/kg/b.wt)
ALP ( $\mu$ moles of phenol/min mg protein)	9.56 $\pm$ 0.33	24.81 $\pm$ 1.02a*	9.35 $\pm$ 0.55 b*	10.0 $\pm$ 1.01 b*	11.2 $\pm$ 1.5 b*	10.4 $\pm$ 1.05
ACP ( $\mu$ moles of phenol/min/ mg of protein)	5.12 $\pm$ 0.32	9.37 $\pm$ 0.56 a*	6.32 $\pm$ 0.45 b*	6.21 $\pm$ 0.39 b*	5.8 $\pm$ 0.41 b*	5.4 $\pm$ 0.37
Total ATPase (mg Pi/100g/min)	2.9 $\pm$ 0.12	1.35 $\pm$ 0.10 a*	2.6 $\pm$ 0.09 b*	2.1 $\pm$ 0.22 b*	2.45 $\pm$ 0.19 b*	2.32 $\pm$ 0.15
Glycogen (mg/100g)	11.00 $\pm$ 1.26	7.50 $\pm$ 0.51 a*	10.00 $\pm$ 0.63 b*	10.33 $\pm$ 1.03 b*	10.50 $\pm$ 0.83 b*	9.83 $\pm$ 1.32
Protein (mg/100 g)	185.1 $\pm$ 19.2	155.2 $\pm$ 10.9 a*	190.5 $\pm$ 14.25b*	192.5 $\pm$ 18.9 b*	189.2 $\pm$ 18.5 b*	191.2 18.2
Lipid peroxidation (nmol MDA/ mg protein)	164.82 $\pm$ 8.15	237.33 $\pm$ 9.11 a*	172.28 $\pm$ 7.89 b*	186.66 $\pm$ 16.32 b*	169.21 $\pm$ 11.63 b*	166.83 $\pm$ 5.84
Glutathione ( $\mu$ mol/g)	9.57 $\pm$ 0.17	7.52 $\pm$ 0.44 a*	9.82 $\pm$ 0.19 b*	9.90 $\pm$ 0.21 b*	8.90 $\pm$ 0.16 b*	9.01 $\pm$ 0.17

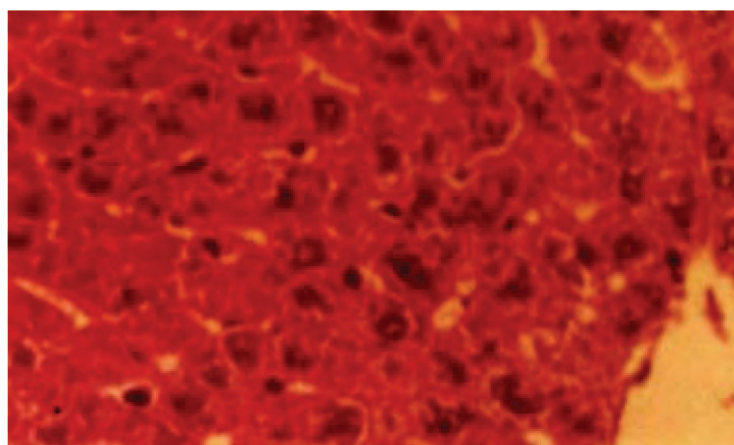
The values are expressed as mean  $\pm$  S.D.; Each group consists of six animals.; Comparisons were made as follows: a: Group II (CCl4-induced) vs. Group I (control); b: Group II vs. Group III (CCl4-induced +*Ricinus communis* extract 250mg/kg/b.wt); Group IV (CCl4-induced +*Ricinus communis* extract 500mg/kg/b.wt); Group-V(CCl4-induced + silymarin 50mg/kg/b.wt); The symbol represents the statistical significance at: \* $p$ <0.05.

into six groups of six animals each and were treated as follows:

- Group I: normal control (vehicle olive oil only)
- Group II: CCl4 (3 ml/kg/b.wt i.p. in olive oil (1:1, v/v), single administration).
- Group III: CCl4 + *R. communis* ethanol extract (250 mg/kg/b.wt, p.o. for five days).
- Group IV: CCl4 + *R. communis* ethanol extract (500 mg/kg/b.wt, p.o. for five days).
- Group V: CCl4 + silymarin (50 mg/kg/b.wt, p.o. for five days).

- Group VI: negative control (*R. communis* ethanol extract 500 mg/kg/b.wt, p.o. for five days).

At the end of the experimental period, all the animals were sacrificed under ether anesthesia. Blood and liver samples were collected. The blood was allowed to clot for 30 min.; serum was separated by centrifuging at 37 °C which was used for biochemical estimations.

**Fig 1C**

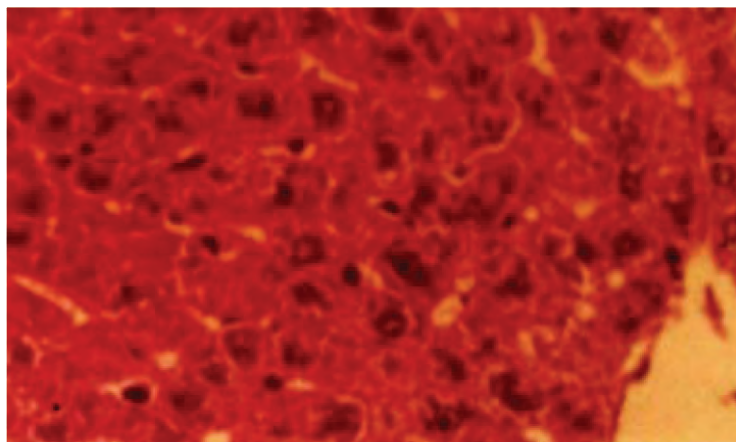


Fig 1D.

#### 2.4. Assessment of hepatoprotective activity

The activities of serum glutamate pyruvate transaminase (SGPT) and serum glutamate oxaloacetate transaminase (SGOT) were assayed by the method of Reitman and Frankel [16]. Estimation of activities of alkaline phosphatase (ALP), acid phosphatase (ACP) by the method of King [17], and total ATPases [18], protein [19], and glycogen content [20], lipid peroxide [21] and glutathione level [22] were also carried out in liver tissue to assess the damage caused by  $\text{CCl}_4$ .

#### 2.5. Histopathological studies

Immediately after sacrifice, a portion of the liver was fixed in 10% formalin. The washed

tissue was dehydrated in descending grades of isopropanol and finally cleared in xylene. The tissue was then embedded in molten paraffin wax and cut into 5  $\mu\text{m}$  thick sections in a rotary microtome. The sections were then stained with haematoxylin and were studied for histopathological changes, i.e. necrosis, fatty changes and lymphocyte infiltration. Histological damages were scored as follows: 0; absent; +: mild; ++: moderate; +++: severe.

#### 2.6. Statistical analysis

The results were expressed as mean $\pm$ S.D. and statistical analysis was performed using ANOVA to determine significant differences between the groups, followed by Student's




Fig 1E.

Newman-Keul's test.  $p < 0.05$  was the implied significance.

### 3. Results

Administration of  $\text{CCl}_4$  to rats caused a significant elevation in serum aspartate, and alanine aminotransferases (Table 1). However, the elevated SGOT and SGPT activity observed in  $\text{CCl}_4$ -treated rats was found to be significantly decreased by prior administration of *Ricinus communis* ethanol extract.

Alterations in the activities of acid phosphatase, alkaline phosphatase, adenosine triphosphatase, glycogen and protein content, lipid peroxidation and glutathione level of liver after single exposure to  $\text{CCl}_4$  were expressed in Table 2. Reduced glutathione and enhanced lipid peroxide level were seen in the  $\text{CCl}_4$ -treated group, whereas the drug treated groups showed a significant rise in glutathione level with the reduction in lipid peroxidation level, when compared to the  $\text{CCl}_4$ -treated group. In  $\text{CCl}_4$ -treated rats, the activities of acid phosphatase and alkaline phosphatase were found to be increased, whereas a decreased glycogen and protein content and adenosine triphosphatase activity was observed when compared to the normal control groups. Administration of *R.*

*communis* ethanol extract to the  $\text{CCl}_4$ -treated rats modulates the above alterations to near normal levels.

As shown in Figure 1A-F and Table 3, liver sections from the control group (Figure 1A) and *R. communis* ethanol extract (500 mg/kg. b.wt) alone treated rats (Figure 1F) showed normal lobular architecture and normal hepatic cells. The liver section from animals given  $\text{CCl}_4$  showed increased cytoplasmic staining and infiltration of mono nuclear cells around the portal triad and in the lobule (Figure 1B). The histological pattern of the liver of the  $\text{CCl}_4$ -induced rats treated with *R. communis* ethanol extract (Figure 1C and 1D) and silymarin (Figure 1E) showed marked improvement and return to normal architecture, respectively.

### 4. Discussion

$\text{CCl}_4$ -induced hepatic injury is often used as a model for hepatoprotective drug screening and the extent of the hepatic damage is assessed by the level of release cytoplasmic transaminases (SGOT and SGPT) in circulation [23]. The present study revealed a significant increase in the activities of SGOT and SGPT in serum (Table 1) and elevated acid and alkaline phosphatases (ALP) (Table 2) in liver on exposure to  $\text{CCl}_4$ , indicating

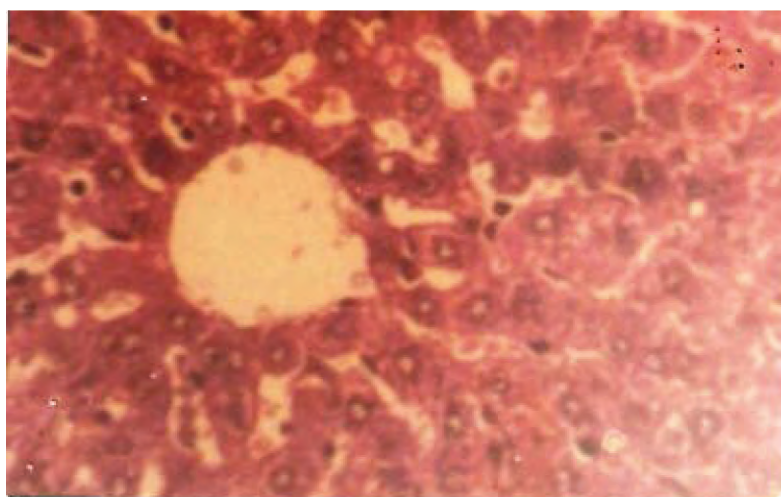


Fig 1F.

**Table 3.** Effect of the *R. communis* ethanol extract on histopathological damages induced by CCl<sub>4</sub> injection in rats.

Microscopic observation			
Groups	Necrosis	Fatty changes	Infiltration of lymphocyte
Control	0	0	0
CCl <sub>4</sub> (3ml/kg/b.wt, i.p.)	+++	+++	+++
CCl <sub>4</sub> (3ml/kg/b.wt, i.p.) + <i>R. communis</i> ethanol extract (250mg/kg/b.wt, p. o)	++	++	++
CCl <sub>4</sub> (3ml/kg/b.wt, i.p.) + <i>R. communis</i> ethanol extract (500mg/kg/b.wt, p. o)	+	+	+
CCl <sub>4</sub> (3ml/kg/b.wt, i.p.) + silymarin (50mg/kg/b.wt, p. o.)	+	0	+
Negative control ( <i>Ricinus communis</i> ethanol extract 500mg/kg/b.wt, p. o	+	0	+

0; absent; +: mild; ++: moderate; +++: severe; rats were injected (i.p.) with *R. communis* ethanol extract for five days after the injection of CCl<sub>4</sub> (3ml/kg/b.wt, i.p.). Histopathological damages were assessed as explained under materials and methods.

considerable hepatocellular injury. Administration of *R. communis* ethanol extract at two different dose levels attenuated the increased levels of marker enzymes, observed in CCl<sub>4</sub>-induced rats. The hepatoprotective effect of the *R. communis* ethanol extract was further supported by the limited extent of histological changes (Figure 1), in *R. communis* treated CCl<sub>4</sub>-induced rats. This is in agreement with the commonly accepted view that serum levels of transaminases return to normal with healing of hepatic parenchyma and the regeneration of hepatocytes [24].

CCl<sub>4</sub> is believed to be metabolized by microsomal CYP450 in the liver to a highly reactive trichloromethyl free radical, which can start a chain of reactive free radical formation resulting in peroxidation of lipids and damage to proteins and cell components [5]. The level of lipid peroxide is a measure of membrane damage and alterations in structure and function of cellular membranes. Glutathione protect cells against electrophilic attacks provided by xenobiotics such as free radicals and peroxides. The elevation of MDA levels, which is one of the end products of lipid peroxidation in the liver tissue, and reduction of hepatic GSH levels are important indicators in CCl<sub>4</sub>-intoxicated rats [25]. In this study, enhanced liver lipid peroxidation and reduced glutathione level were seen in

Group II CCl<sub>4</sub> treated rats (Table 2). However, *R. communis* extract treatment, prevented glutathione depletion with reduction in lipid peroxidation level in CCl<sub>4</sub>-induced rats when compared to CCl<sub>4</sub>-treated control group. The *R. communis* extract with the potentiality to scavenge the free radicals contains flavanoids and tannins. Flavanoids and tannins have been reported to have anti-peroxidative effects [26]. Moreover recently *R. communis* root extract was also found to have free radical scavenging activity [27]. Thus, this finding suggests that the *R. communis* extract was effective in bringing about functional improvement of hepatocytes.

The decreased hepatic glycogen content, and adenosine triphosphatase activity observed in CCl<sub>4</sub> induced rats (Table 2) in our study agrees with previous reports [28]. Glycogen is the main source of energy in the liver [29], so the reduced glycogen content observed in CCl<sub>4</sub> induced rats may be due to excess requirement of energy in liver. CCl<sub>4</sub> intoxication is capable of initiating cell injury and cellular sites for free radical generation include mitochondria, endoplasmic reticulum and plasma membrane. A significant fall in the activity of adenosine triphosphatase observed in CCl<sub>4</sub> induced rats may be due to

the structural and functional disorganization of mitochondria assembly. Upon *R. communis* extract treatment to CCl<sub>4</sub> induced rats, the above said changes were found to be restored significantly when compared to CCl<sub>4</sub> induced rats.

The ability of a hepatoprotective drug to reduce the injurious effects or to preserve the normal hepatic physiological mechanisms, which have been disturbed by a hepatotoxin, is the index of its protective effects [30]. It is reported earlier that fresh leaves and aqueous extract of *R. communis* offered protection against CCl<sub>4</sub>-induced hepatic damage in albino rats [31]. In our study, our results demonstrated that the possible hepatoprotective mechanisms of the ethanol extract of *R. communis* leaves on CCl<sub>4</sub>-induced hepatic damage in rats. Histopathological examinations also show that *R. communis* ethanol extract (250/500mg/kg/b.wt) at both levels of dosage offer hepatoprotection. In addition, this plant extract up to an oral dose of 1 g/kg was found to be devoid of any lethal effects and no apparent behavioral change was observed.

## 5. Conclusions

In conclusion, the present study has demonstrated that the ethanolic extract of *R. communis* has hepatoprotective effect against CCl<sub>4</sub>-induced hepatotoxicity in rats. The beneficial effect of the *R. communis* ethanol extract may be due to the presence of some flavanoids that may have membrane stabilizing and antiperoxidative effects. Thus, this result suggests that the flavanoids and tannins present in the *R. communis* ethanol extract might efficiently increase the regenerative and reparative capacity of the liver. Although *R. communis* ethanol extract has comparable hepatoprotective effect with silymarin in our study, clarification of the hepatoprotective mechanism and the active components of the *R. communis* extract need

further investigation.

## References

- [1] Wang N, Li P, Wang Y, Peng W, Wu Z, Tan S, Liang S, Shen X, Su WW. Hepatoprotective effect of Hypericum japonicum extract and its fractions. *J Ethanopharmacol* 2008; 116: 1-6.
- [2] Al-Shabanah OA, Alam K, Nagi MN, Al-Rikabi AC, Al-Bekairi AM. Protective effect of aminoguanidine, a nitric oxide synthetase inhibitor against CCl<sub>4</sub>-induced hepatotoxicity in mice. *Life Sci* 2000; 66: 265-70.
- [3] Olantunde Farombi E. Mechanisms for the hepatoprotective action of kolaviron: studies on hepatic enzymes, microsomal lipids and lipid peroxidation in carbontetra chloride-treated rats. *Pharmacol Res* 2000; 42: 75-80.
- [4] Agarwal M, Srivastava VK, Saxena KK, Kumar A. Hepatoprotective activity of Beta vulgaris against CCl<sub>4</sub>-induced hepatic injury in rats. *Fitoterapia* 2006; 77: 91-3.
- [5] Jamshidzadeh A, Fereidooni F, Salehi Z, Niknahad H. Hepatoprotective activity of Gundelia tourenfortii. *J Ethanopharmacol* 2005; 101: 233-7.
- [6] Ivan A. Chemical constituents, traditional and modern uses. In: Medicinal plants of the world. Totowa, NJ: *Ross Humana Press Inc.*, 1998; pp. 375-95.
- [7] Kiritikar KR, Basu BA. Indian medicinal plants. Shiva Publishers: Dehradun, India 1991; 3: 2274-7.
- [8] Visen P, Shukla B, Patnaik G, Tripathi S, Kulshreshtha D, Srimal R, Dhawan B. Hepatoprotective activity of *R. communis* leaves. *Intl J Pharmacog* 1992; 30: 241-50.
- [9] Dhar ML, Dhar MM, Dhawan BN, Mehrotra BN, Ray C. Screening of Indian plants for biological activity. Part I. *Indian J Exp Biol* 1968; 6: 232-47.
- [10] Capasso F, Mascolo N, Izzo AA, Gaginella TS. Dissociation of castor oil induced diarrhea and intestinal mucosal injury in rat: effect of NG-nitro-L-arginine methyl ester. *Br J Pharmacol* 1994; 113: 1127-30.
- [11] Abraham Z, Bhakuni SD, Garg HS, Goel AK, Meharotra BN, Patnaik GK. Screening of Indian plants for biological activity. Part XII. *Indian J Exp Biol* 1986; 24: 48-68.
- [12] Verpoorte R, Dihal PP. Medicinal plants of the Surinam. IV. Antimicrobial activity of some medicinal plants. *J Ethanopharmacol* 1987; 21: 315-8.
- [13] Kang SS, Cordell A, Soejarto DD, Fong HHS.



- Alkaloids and flavanoids from *Ricinus communis*. *J Nat Prod* 1985; 48: 155-6.
- [14] Khogali A, Barakat S, Abou-Zeid H. Isolation and identification of the phenolics from *Ricinus communis* L. *Delta J Sci* 1992; 16: 198-211.
- [15] Chrungoo VJ, Singh K, Singh J. Silymarin mediated differential modulation of toxicity induced by carbontetra chloride, paracetamol and D-galactosamine in freshly isolated rat hepatocytes. *Indian J Exp Biol* 1997; 35: 611-7.
- [16] Reitman S, Frankel S. A colorimetric method for the determination of serum glutamic oxaloacetic and glutamic pyruvic transaminases. *Am J Clin Pathol* 1957; 28: 56-63.
- [17] King J. The hydrolases-acid and alkaline phosphatases, In: Van D, (editor). *Practical clinical enzymology*. London: *Nostrand Company Limited*, 1958; pp.191-208.
- [18] Seth PK, Tangari KK. Biochemical effects of newer salicylic acid congenesis. *J Pharm Pharmacol* 1966; 18: 831-3.
- [19] Lowry OH, Rosebrough NJ, Farr AI, Randall RJ. Protein measurement with the folin phenol reagent. *J Biol Chem* 1951; 193: 265-75.
- [20] Hassid WZ, Abraham S. Chemical procedures for analysis of polysaccharides. *Methods Enzymol* 1957; 3: 34-50.
- [21] Ohkawa H, Ohishi N, Yagi K. Assay for lipid peroxides in animal tissues by thiobarbituric acid reaction. *Anal Biochem* 1997; 95: 351-8.
- [22] Griffith OW. Determination of glutathione and glutathione disulfide using glutathione reductase and 2-vinylpyridine. *Anal Biochem* 1980; 106: 207-12.
- [23] Janbaz KH, Saeed SA, Gilani AH. Protective effect of rutin on paracetamol and CCl<sub>4</sub> induced hepatotoxicity in rodents. *Fitoterapia* 2002; 73: 557-63.
- [24] Thabrew M, Joice P, Rajatissa W. A comparative study of the efficacy of *Pavetta indica* and *Osbeckia octandra* in the treatment of liver dysfunction. *Planta Medica* 1987; 53: 239-41.
- [25] Souza MF, Rao VSN, Silveira ER. Inhibition of lipid peroxidation by ternatin, a tetramethoxyflavone from *Egletes viscosa* L. *Phytomedicine* 1997; 4: 25-9.
- [26] Yokozawa T, Chen CP, Dong E, Tanaka T, Nonaka GI, Nishioka I. Study on the inhibitory effect of tannins and flavanoids against the 1,1-diphenyl-2-picrylhydrazyl radical. *Biochem Pharmacol* 1998; 56: 213-22.
- [27] Ilavarasan R, Mallika M, Venkataraman S. Anti-inflammatory and free radical scavenging activity of *Ricinus communis* root extract. *J Ethanopharmacol* 2006; 103: 478-80.
- [28] Jadon A, Bhadauria M, Shukla S. Protective effect of *Terminalia bellerica* Roxb. and gallic acid against carbon tetrachloride induced damage in albino rats. *J Ethanopharmacol* 2007; 109: 214-18.
- [29] Krehenbuhl S, Weber Jr FL, Brans E. Decreased hepatic glycogen content and accelerated response to starvation in rats with carbon tetrachloride induced cirrhosis. *Hepatology* 1991; 14: 1189-95.
- [30] Yadav NP, Dixit VK. Hepatoprotective activity of leaves of *Kalanchoe pinnata* Pers. *J Ethanopharmacol* 2003; 86: 197-202.
- [31] Natu MV, Agarwal S, Agarwal SL, Agarwal S. Protective effect of *Ricinus communis* leaves in experimental liver injury. *Ind J Pharmacol* 1977; 9: 265-8.

Conflict of Interest Statement:

All authors hereby declaring that there is no of conflict of interest against any organizations, consultancies, and grants etc.